

# The efficacy of fractional CO<sub>2</sub> laser resurfacing in the treatment of facial acne scars

Abdul Hakeem Mohammad Saeed, Salaiman Ayed Alsaari

Department of Internal Medicine, Najran University, Najran, Saudi Arabia

Correspondence to: Abdul Hakeem Mohammad Saeed, E-mail: hakeemsaeed@gmail.com

Received: April 07, 2018; Accepted: April 29, 2018

## ABSTRACT

**Background:** Acne is a common condition with prevalence as high as 80% among adolescents and often it causes atrophic scars. Laser resurfacing is an effective treatment for acne scars. However, post-treatment adverse effects are often induced. Fractional laser photothermolysis has been designed to create microscopic thermal wounds to achieve skin rejuvenation without significant side effects. **Objectives:** The aim of this study is to assess the efficacy and safety level of fractional CO<sub>2</sub> laser in atrophic acne scars treatment. **Materials and Methods:** Forty patients between 18 and 40 years of both sexes with atrophic acne scars seen in the Department of Dermatology at Najran University Hospital in Najran, Saudi Arabia, were treated with 4–6 sessions of fractional CO<sub>2</sub> laser resurfacing. The result was evaluated objectively at each follow-up visit and 3 months after the last laser session using a quartile grading scale. Patient improvements were classified as excellent when the improvement was >50% in scar outcome and appearance of skin, good if 25–50% response, and poor when the response <25%. Patient satisfaction and side effects were monitored and recorded for up to 3 months after the last laser session. **Results:** All patients were with moderate-to-severe atrophic scars. There were 16 patients with predominantly rolling scar, nine patients with predominantly pitting scar, and 15 patients with mixture scars. The cheek was the most commonly affected site (95%). At the time of final assessment, an excellent response was observed in 14 patients (37.5%) while 16 (40%) and 10 patients (25%) demonstrated a good and poor response, respectively. Rolling scar responds better to the treatment than other types of acne scar ( $P = 00$ ). Side effects were transient and mild, and 62.5% of patients were very satisfied or only satisfied with the treatment. **Conclusions:** Fractional CO<sub>2</sub> laser resurfacing as monotherapy appeared to be a safe and effective option for atrophic acne scar treatment especially rolling scars with minimal adverse effects.


**KEY WORDS:** Acne Scars; Pitting Scar; Rolling Scars; Fractional CO<sub>2</sub> Laser Resurfacing

## INTRODUCTION

Acne is a common condition with prevalence as high as 80% among adolescents.<sup>[1]</sup> All body areas with high concentrations of pilosebaceous glands may possibly be involved, but the most common affected areas include the face, back, and chest.<sup>[2]</sup> Acne

lesions can result in permanent scarring with a marked impact on quality of life. Genetic factors, disease severity, and delay in treatment are the main factors influencing scar formation.<sup>[2]</sup>

Atrophic scars can result from any inflammatory skin disease causing sufficient damage to the epidermis and to the dermal collagen. The most common causes of atrophic scars, especially on the face, are severe nodular or nodulocystic acne, infections such as varicella and herpes simplex, trauma including burns and finally, surgical procedures. Facial scars resulting from any of these etiologies are associated with psychological trauma and loss of self-esteem.<sup>[3]</sup> Successful treatment of these scars can be a satisfying experience to the patient and the treating physician.

Access this article online	
Website: <a href="http://www.ijmsph.com">http://www.ijmsph.com</a>	Quick Response code
DOI: 10.5455/ijmsph.2018.0412829042018	

International Journal of Medical Science and Public Health Online 2018. © 2018 Abdul Hakeem Mohammad Saeed and Salaiman Ayed Alsaari. This is an Open Access article distributed under the terms of the Creative Commons Attribution 4.0 International License (<http://creativecommons.org/licenses/by/4.0/>), allowing third parties to copy and redistribute the material in any medium or format and to remix, transform, and build upon the material for any purpose, even commercially, provided the original work is properly cited and states its license.

Facial scars resulting from acne are either hypertrophic or atrophic depending on whether they are elevated or depressed in relation to the skin surface. The atrophic facial scars are divided into different morphological types depending on the shape and depth of the scars.<sup>[4,5]</sup> The four main morphological types of atrophic post acne scars are ice-pick pitted scars, superficial or deep boxcar scars, rolling scars, and linear scars. Treatment of each morphological scar type varies, and while one scar type responds the best to some treatment modality, the same treatment option may not be necessarily effective in other type of scars.<sup>[6]</sup>

Facial resurfacing with fractional lasers is currently claimed to be one of the most effective treatment options for facial scars.<sup>[7,8]</sup> Fractional lasers treat only a 'fraction' or a column of the affected skin leaving intervening areas of skin untreated. These untreated areas help in rapid reepithelization of the skin, minimizing the chances of prolonged and serious adverse effects.<sup>[9]</sup> Fractional lasers are divided into either non-ablative or ablative fractional lasers. While the former is claimed to be the safer of the two types, the latter has been shown to be more effective in treating facial imperfections with better patient satisfaction.<sup>[10]</sup> Fractional CO<sub>2</sub> laser resurfacing has been used in the treatment of atrophic scars with varying degrees of success.<sup>[11-14]</sup> Adverse effects in the form of persistent post-treatment erythema, crusting, post-inflammatory hyperpigmentation, purpura and even aggravation of scarring have been described as adverse reactions to this treatment option.<sup>[15,16]</sup> For fractional laser resurfacing to be effective, the depth of penetration of the laser is a very important factor, and it is important to realize that the depth shows a non-linear correlation with the density and energy settings that are used with an individual laser.<sup>[17]</sup>

For the present study, we used a fractional CO<sub>2</sub> laser Lutronic, Korea marketed by Imdad medical instrument supply. The machine has one hand-piece with four tips. The laser has dual-mode technology (static-dynamic) and articulated arm with scanner and surgical handpiece.

## MATERIALS AND METHODS

This study was conducted at najran university hospital which is located in the southern region of Saudi Arabia. The study participants were all adult patients (Aged between

18 and 40 years old), of Fitzpatrick skin types III-V, who were presented with moderate-to-severe atrophic facial acne scars in an outpatient setting between FEBRUARY 2014 and JANUARY 2018. All patients were emotionally balanced with realistic expectation with facial acne scars. Exclusion criteria were known photosensitivity, pregnancy or lactation, a history of hypertrophic or keloidal scarring, using isotretinoin, and a history of active acne, or active infections.

Included patients underwent a detailed history and full clinical examination to determine the presence of active acne lesions, the affected sites, Fitzpatrick skin type, and type of acne scar as proposed by Jacob *et al.* [Table 1].<sup>[4]</sup> Severity of acne scar was assessed using qualitative scarring grading system, which was developed by Goodman and Baron as given in Table 2.<sup>[5]</sup> Those with moderate-to-severe atrophic facial acne scars are included in this study.

The patients informed to stop topical creams one week before the session and to stop any cosmetic in between the sessions. Patients were explained about the outcome, side effects, and complications of the procedure. After written informed consent was obtained from all participants, an early picture showing the acne scars to be treated using good camera angle and light settings. Then, topical anesthetic cream (EMLA) was applied for 30 min to an hour before the laser session. After that, the treatment area was cleaned with mild cleanser and dried with sterile gauze. The session was then delivered to each atrophic scar present. Fluence ranging from 15 to 25 j/cm<sup>2</sup> was used at densities of 100–150 MTZ/cm<sup>2</sup>, thus providing about 40–45 mj of energy and an ablation depth of 1.0–1.2 mm at each spot. A single or double pass was used over each scar along with its margins. Each morphological type of scar was treated in a similar manner, and the patient was advised skin cooling with ice-packs for 5–10 minutes after the procedure to take care of post-treatment erythema, edema, and burning sensation.

Postoperative care included application of topical Fucicort cream on both sides of the face, twice daily for the next week after each session. Sun avoidance and sun protection with a broad spectrum sunscreen were advised. Those patients with a history of recurrent herpes were informed to use oral acyclovir. Every patient had from 4 to 6 laser sessions repeated monthly. The same laser setting was applied for every patient.

**Table 1:** Acne scar classification (adapted from Jacob *et al.*)

Acne scars subtype	Clinical features
Ice-pick	Ice-pick scars are narrow (<2 mm), deep, sharply demarcated tracts that extend vertically to the deep dermis or subcutaneous tissue
Rolling	Rolling scars may reach ≥5 mm in diameter. They have a rolling or undulating appearance that occurs from fibrous tethering of the dermis to the subcutis
Boxcar	Boxcar scars are oval depressions with sharply demarcated vertical edges. They are wider at the surface than ice-pick scars and do not taper to a point at the base

Most patients satisfied at the fourth sessions and those who unsatisfied were undergone for further one or two sessions. Control picture and further photographs after each follow up visits were taken with the same angle, head position and light exposure. Then, final evaluation was made by an observer at the final follow-up visit, and then after the last laser session by 3 months. We used quartile grading scale to evaluate the results objectively. 0, 1, 2, and 3 scores were used and given if the results were <25%, 25–50%, 51–75% and >75%, respectively. Patient improvements were classified as excellent when the score 2 or more, good if the score was 1, and poor when there was 0 score. Patients were asked about their rate of satisfaction at the final visit, and they were classified into very satisfied, only satisfied, slightly satisfied, or completely unsatisfied.

Moreover, side effects, especially erythema, superficial crusting, mild transient edema, acneiform lesions, and post-inflammatory hyperpigmentation were monitored and recorded for up to 3 months after the last laser session.

### Statistical Analysis

Statistical analysis was performed using Statistical package for social sciences. Frequencies, mean and standard deviation for each of the demographic, and baseline clinical data were calculated. Statistical significance between different variables was evaluated by the use of Pearson Chi-square test. For all of the statistical analyses,  $P < 0.05$  was considered to be statistically significant.

## RESULTS

Forty patients were included in this study. Their mean age was 26.4 years (standard deviation = 5.4), having a minimum of 18 years and a maximum of 40 years. There were 12 (30%)

males and 28 (70%) females with a male-to-female ratio of 0.43. There were nine patients with Fitzpatrick skin type 3, 25 patients with skin type 4, and five patients with skin type 5.

Based on Goodman and his collages baron classification system, all patients were with moderate-to-severe atrophic scars, 31% had moderate acne scar, and 9% with severe grade of acne scars. The distribution of patients according to morphologic types was as follows: 40% of patients with acne scar had predominantly rolling scar, 37.5% had mixture of various morphologic scar subtypes, and 22.5% had predominantly pitting scar. The cheek was found to be the most commonly affected site (95%), followed by the temples (57.5%), and forehead (17.5%). Chin was affected in four patients (10%) [Table 3].

A positive response with either good or excellent results was reported in 30 patients corresponding to 75% of the study group. Of these 30 responders, there were seven patients (17.5%) in whom >75% improvement was seen in scars and skin texture while in 7 others, the improvement was in the range of 51–75%. Thus, excellent response (score 2 or more on quartile grading scale) was observed in a total of 14 patients (37.5%) (Figures 1a and b). Sixteen patients (40%) showed a good response while poor response was noted in 10 patients (Table 4, Figures 2a, b and 3a, b).

Patient surveys with regard to overall satisfaction revealed that 25 (62.5%) were very satisfied or satisfied and six (15%) were slightly satisfied. For the remaining nine cases, the improvement achieved was not up to their expectations.

As shown in Table 4, the results from this study demonstrate that rolling scar responds better to the fractional laser resurfacing monotherapy than other types of acne scar, and it was statistically significant ( $P = 0.00$ ). In fact, 92.9%

**Table 2:** Qualitative scar grading system

Grades of post-acne scarring	Level of disease	Clinical features
1	Macular	These scars can be erythematous, hyper-or hypopigmented flat marks. They do not represent a problem of contour like other scar grades but of color
2	Mild	Mild atrophy or hypertrophy scars that may not be obvious at social distances of 50 cm or greater and may be covered adequately by makeup or the normal shadow of shaved beard hair in men or normal body hair if extrafacial
3	Moderate	Moderate atrophic or hypertrophic scarring that is obvious at social distances of 50 cm or greater and is not covered easily by makeup or the normal shadow of shaved beard hair in men or body hair if extrafacial, but is still able to be flattened by manual stretching of the skin (if atrophic)
4	sever	Severe atrophic or hypertrophic scarring that is evident at social distances greater than 50 cm and is not covered easily by makeup or the normal shadow of shaved beard hair in men or body hair if extrafacial and is not able to be flattened by manual stretching of the skin

**Table 3:** Demographic and baseline clinical data of participants

Parameters	Gender		Total (%)
	Male (%)	Female (%)	
Age (mean)	27	26.14	26.4
Fitzpatrick skin type			
3.00	4 (10.0)	6 (15.0)	10 (25.0)
4.00	5 (12.5)	20 (50.0)	25 (62.5)
5.00	3 (7.5)	2 (5.0)	5 (12.5)
Scar grade			
Moderate	9 (22.5)	22 (55.0)	31 (77.5)
Sever	3 (7.5)	6 (15.0)	9 (22.5)
Scar type			
Predominantly rolling scar	5 (12.5)	11 (27.5)	16 (40.0)
Predominantly ice-pick scar	3 (7.5)	6 (15.0)	9 (22.5)
Mixture scars	4 (10.0)	11 (27.5)	15 (37.5)
Site			
Cheeks	12 (30.0)	26 (65.0)	38 (95.0)
Temples	7 (17.5)	16 (40.0)	23 (57.5)
Chin	1 (2.5)	3 (7.5)	4 (10.0)
Forehead	3 (7.5)	4 (10.0)	7 (17.5)

of excellent response (score 2 or more) to the treatment was presented in the predominantly rolling type of scars. Whereas, patients who achieved the minimum improvement score (score 0) had predominantly pitting scars (80%).

Most of the patients had associated adverse effects noted to the treatment regimen, which found to be extremely variable and transient. These included 95% with mild erythema, 77.5% with superficial crusting, and 67.5% with transient edema. The only significant adverse effect observed was post-inflammatory hyperpigmentation that developed in two cases in our study. This pigmentation resolved with topical therapy over a period of 2–3 months. There were no major adverse effects observed such as persistent erythema, herpes labialis flare-up, scarring, or keloid formation in any of the cases.

## DISCUSSION

In the case of acne scars, the fractional resurfacing CO<sub>2</sub> laser gives excellent results.<sup>[18,19]</sup> However, the prolonged erythema lasting for weeks, crusting and oozing, and post-inflammatory hyperpigmentation are recognized side effects that associated with these modalities of treatment particularly in the colored skin which limit the usefulness of this option.<sup>[20]</sup> Hence, the technology of fractional CO<sub>2</sub> laser avoids many of these undesirable effects as only a “fraction” of the skin is shot, and the epidermis and his integrity are not compromised. For that the microscopic wound produced by the laser beams is enclosed by normal, unlasered tissue, the healing is quick,

and the unwanted side effects are minimized to a good degree. In our study, all of the cases had moderate-to-severe atrophic post-acne scars. In the majority of cases (25 out of 40), all the different morphological types of atrophic scars were present. The most common sites involved were the cheeks followed by temples and forehead. At the 4-month follow-up visit after the last laser session, a positive response with either good or excellent results was documented in 30 patients (75%) of the study group. Of these 30 responders, >75% improvement was seen in seven patients (17.5%). While in 7 others, the improvement was in the range of 51–75%. Thus, excellent response (score 2 or more on quartile grading scale) was observed in a total of 14 patients (37.5%). Sixteen patients (40%) showed a good response while 10 patients failed to demonstrate any significant response to treatment with <25% improvement on the quartile scale. Patient satisfaction assessment shows that about 77.5% (31 cases out of the total of 40) were satisfied with the treatment results. For the remaining nine cases, the improvement achieved was not up to their expectations. This result is in obtained with that of previous studies on the photothermolysis resurfacing CO<sub>2</sub> fractional laser in atrophic acne scars.<sup>[11,21-23]</sup> No any significant adverse effects were noted on the long term from the resurfacing fractional laser. However, there is certainly some degree of erythema and crusting with post laser pigmentation mostly noted with more colored skin. This crusting makes some difficulties for patients to restart their work for many days after each session. Hence, the best time to do this procedure in the weekend to reduce the sick leave days after the laser sessions. In addition, post-inflammatory hyperpigmentation was observed in five patients in our study

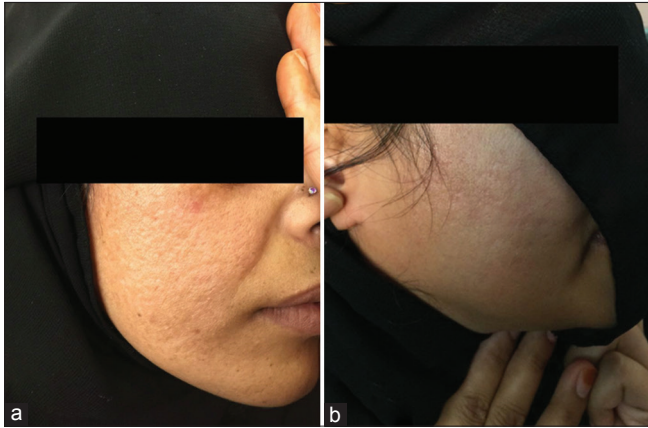
**Table 4:** Association of the treatment response with patient and acne scar characteristics

Characteristics	Treatment Response			Total (%)	P value
	Poor (score 0) (%)	Good (score 1) (%)	Excellent 0 (≥ score 2) (%)		
Gender					
Male	3 (7.5)	5 (12.5)	4 (10.0)	12 (30.0)	0.98
Female	7 (17.5)	11 (27.5)	10 (25.0)	28 (70.0)	
Total	10 (25.0)	16 (40.0)	14 (35.0)	40 (100.0)	
Fitzpatrick skin type					
3.00	0 (0.0)	4 (10.0)	6 (15.0)	10 (25.0)	0.07
4.00	7 (17.5)	10 (25.0)	8 (20.0)	25 (62.5)	
5.00	3 (7.5)	2 (5.0)	0 (.0)	5 (12.5)	
Total	10 (25.0)	16 (40.0)	14 (35.0)	40 (100.0)	
Scar grade					
Moderate	8 (20.0)	12 (30.0)	11 (27.5)	31 (77.5)	0.95
Sever	2 (5.0)	4 (10.0)	3 (7.5)	9 (22.5)	
Total	10 (25.0)	16 (40.0)	14 (35.0)	40 (100.0)	
Scar type					
Predominantly rolling scar	1 (2.5)	2 (5.0)	13 (32.5)	16 (40.0)	0.00
Predominantly ice-pick scar	8 (20.0)	1 (2.5)	0 (.0)	9 (22.5)	
Mixture scars	1 (2.5)	13 (32.5)	1 (2.5)	15 (37.5)	
Total	10 (25.0)	16 (40.0)	14 (35.0)	40 (100.0)	
Satisfaction					
Very satisfied	1 (2.5)	1 (2.5)	6 (15.0)	8 (20.0)	0.00
Only satisfied	0 (.0)	9 (22.5)	8 (20.0)	17 (42.5)	
Slightly satisfied	0 (.0)	6 (15.0)	0 (.0)	6 (15.0)	
Completely unsatisfied	9 (22.5)	0 (.0)	0 (.0)	9 (22.5)	
Total	10 (25.0)	16 (40.0)	14 (35.0)	40 (100.0)	
Site					
Cheeks	8 (20.0)	16 (40.0)	14 (35.0)	38 (95.0)	
Temples	5 (12.5)	7 (17.5)	11 (27.5)	23 (57.5)	
Chin	0 (.0)	1 (2.5)	3 (7.5)	4 (10.0)	
Forehead	1 (2.5)	3 (7.5)	3 (7.5)	7 (17.5)	
Total	10 (25.0)	16 (40.0)	14 (35.0)	40 (100.0)	

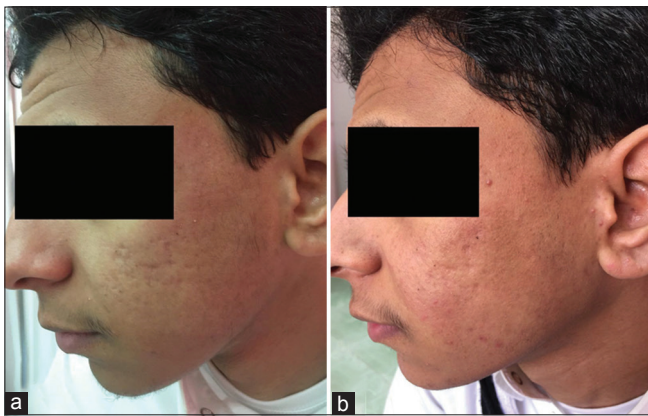
which improved by application of Kligman formula for 3 months. We informed all the patients to use broad spectrum photobloc cream intensively, especially in the days after the procedure and to avoid exposure to sunlight. The response was the best with rolling acne scars, while the response to ice-pick pitted scars was the least in study population. Hence, the fractional laser resurfacing monotherapy is not enough therapy to get rid the pitted scars. Thus, if ice-pick scars are predominantly in patient, the patient is likely to be unsatisfied with fractional laser resurfacing as monotherapy alone. Here, the patient would need either additional modalities of treatment as the case with chemical peeling (TCA 80–100%) technique or with surgical methods like with punch excision if practically feasible.<sup>[24,25]</sup>

Many of studies have approved a positive therapeutic effect of ablative resurfacing fractional laser with CO<sub>2</sub> laser. In a

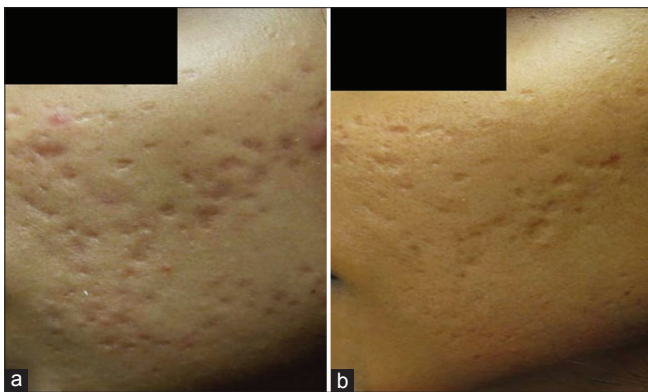
pilot study conducted by Glaich and colleagues,<sup>[21]</sup> seven participants with hypopigmented scarring due to acne (6) and burn (1) reported subjective improvement after fractional resurfacing treatment. Each subject underwent two to four treatments (1,000–2,500MTZ/cm<sup>2</sup> at pulse energies of 7–20 mJ) at 4-week intervals with a mean improvement of 51–75% based on independent physician assessment. Side effects were limited to posttreatment erythema and edema, both resolving within 2–4 days. These findings were recently confirmed by Alster *et al.*<sup>[11]</sup> who investigated the efficacy of fractional laser for facial atrophic acne scars in 53 patients, the largest prospective trial to date. Patients were treated with 8–10 passes at 125–250 MTZ/cm<sup>2</sup>, and fluence of 8–16 J/cm<sup>2</sup> delivering a total energy of 4–6 kJ per session. In this study, masked assessors reported a 25–50% clinical improvement in 91% of patients after a single treatment. Mean clinical scores increased incrementally after each treatment with a



**Figure 1:** (a) Predominant rolling scars in the cheek, (b) four months after the last fourth session with excellent response



**Figure 2:** Rolling scars on the cheek, (b) good response after four sessions of fractional CO<sub>2</sub> laser resurfacing



**Figure 3:** (a) Icepick scars and boxcar scarring (b) Partial Response to four fractional laser resurfacing sessions

51–75% improvement noted in 87% of patients that received three treatments at 4-week intervals. Interestingly, this benefit was maintained over time, as the investigators found no significant difference in clinical scores at the 6-month follow-up. The authors also concluded that fractional laser treatment showed a similar mild and limited side effect profile across all Fitzpatrick skin types. These findings bring further support for a renewed excitement among physicians who treat patients with darker skin types, where lasers have

been of limited utility due to the higher risk of pigmentary alteration. The treatment of a patient with acne scars either moderate or severe is challenging. The different types of scars can be present in the same patient, and the depth of these pittings scars vary in every patient. These multiple factors made the difficulty in the assessment of efficacy and effectiveness of these therapeutic options to judge through all these patients. The wavel ength of 10,600 nm of the fractional CO<sub>2</sub> laser has also been worked in the treatment of post acne scars in both Caucasian<sup>[26-28]</sup> and Asian<sup>[29-31]</sup> patients with skin phenotypes ranging from type one to type four. Chapas *et al.* in their study on atrophic acne scars of the face, documented a good improvement ranging from 26 to 50% in integrity, and atrophy of the skin in all their patients.<sup>[32]</sup> An imaging system of good quality and investigators were used both to analyze the change in the texture of scars. This system of imaging also documented an improvement in the degree of depth of individual scars varied from 43 to 79.9% with a median improvement of 66.8%. The mentioned adverse effects that associated in their study in the patients were resolved without any persistent problem and no one of the patients had any long-term or persistent adverse effects.<sup>[20]</sup> In only single-blinded randomized study on post-acne scars, and other types of facial scars, Hedelund *et al.* reported considerable significant improvement in the texture of skin and atrophy with good patient's satisfaction in regarding with placebo after three sessions of monthly laser with photothermolytic fractional CO<sub>2</sub> equipment.<sup>[33]</sup> This study was applied on 13 patients, and the patients were denoted a good improvement with this treatment option; however, in this study, higher energies of 48–56 mJ were used with a treatment density of 13%. Sung Bin Cho demonstrated in their study the effectiveness profile and safety level of resurfacing photothermolysis fractional CO<sub>2</sub> laser in post-acne scars.<sup>[31]</sup>

The therapeutic results obtained with fractional laser resurfacing are lacking the uniform objective assessment of the satisfaction achieved therapeutically. The large portion of the clinical studies on resurfacing fractional laser procedure have been used with quartile grading systems or the satisfaction of the patient as the criteria to determine the results. Both of these criteria conflicts with subjective bias and the need for a correct fully objective tool that we need to use across the spectrum of pitting acne scars to determine any therapeutic benefit.<sup>[34]</sup> In addition, there are just a few studies that reported the therapeutic benefits in various morphological types of acne scars.<sup>[35-39]</sup> All other studies have make a generalized statement on the results achieved without taking in to consideration the various responses between the morphology of scar types.

## CONCLUSION

Treatment of atrophic acne scars with fractional CO<sub>2</sub> laser resurfacing as monotherapy seems to be effective, and without

significant side effects, even in darker-skinned patients. We encourage future research to better establish optimal laser settings in different populations. We also recommend that future researchers adhere to a uniform rating scale to help standardize results for comparison.

## ACKNOWLEDGMENTS

We are thankful to our patients and staff of Dermatology Department, Najran University Hospital, Najran, Saudi Arabia, for their cooperation in various aspects of this work.

## REFERENCES

- Gozali MV, Zhou B. Effective treatments of atrophic acne scars. *J Clin Aesthet Dermatol* 2015;8:33-40.
- Fabbrocini G, Annunziata MC, D'Arco V, De Vita V, Lodi G, Mauriello MC, *et al.* Acne scars: Pathogenesis, classification and treatment. *Dermatol Res Pract* 2010;2010:893080.
- Layton AM. Psychosocial aspects of acne vulgaris. *J Cutan Med Surg* 1998;2 Suppl 3:19-23.
- Jacob CI, Dover JS, Kaminer MS. Acne scarring: A classification system and review of treatment options. *J Am Acad Dermatol* 2001;45:109-17.
- Goodman GJ. Postacne scarring: A review of its pathophysiology and treatment. *Dermatol Surg* 2000;26:857-71.
- Kadunc BV, Trindade de Almeida AR. Surgical treatment of facial acne scars based on morphologic classification: A Brazilian experience. *Dermatol Surg* 2003;29:1200-9.
- Geronemus RG. Fractional photothermolysis: Current and future applications. *Lasers Surg Med* 2006;38:169-76.
- Rivera AE. Acne scarring: A review and current treatment modalities. *J Am Acad Dermatol* 2008;59:659-76.
- Hantash BM, Mahmood MB. Fractional photothermolysis: A novel aesthetic laser surgery modality. *Dermatol Surg* 2007;33:525-34.
- Cho SB, Lee SJ, Cho S, Oh SH, Chung WS, Kang JM, *et al.* Non-ablative 1550-nm erbium-glass and ablative 10600-nm carbon dioxide fractional lasers for acne scars: A randomized split-face study with blinded response evaluation. *J Eur Acad Dermatol Venereol* 2010;24:921-5.
- Alster TS, Tanzi EL, Lazarus M. The use of fractional laser photothermolysis for the treatment of atrophic scars. *Dermatol Surg* 2007;33:295-9.
- Gold MH, Heath AD, Biron JA. Clinical evaluation of the smartSkin fractional laser for the treatment of photodamage and acne scars. *J Drugs Dermatol* 2009;8:s4-8.
- Hu S, Chen MC, Lee MC, Yang LC, Keoprasom N. Fractional resurfacing for the treatment of atrophic facial acne scars in Asian skin. *Dermatol Surg* 2009;35:826-32.
- Rahman Z, Tanner H, Jiang K. Treatment of atrophic scars with the 1550nm erbium-fiber fractional laser. *Lasers Surg Med* 2006;38:24.
- Campbell TM, Goldman MP. Adverse events of fractionated carbon dioxide laser: Review of 373 treatments. *Dermatol Surg* 2010;36:1645-50.
- Metelitsa AI, Alster TS. Fractionated laser skin resurfacing treatment complications: A review. *Dermatol Surg* 2010;36:299-306.
- Sardana K, Garg VK, Arora P, Khurana N. Histological validity and clinical evidence for use of fractional lasers for acne scars. *J Cutan Aesthet Surg* 2012;5:75-90.
- Alexiades-Armenakas MR, Dover JS, Arndt KA. The spectrum of laser skin resurfacing: Nonablative, fractional, and ablative laser resurfacing. *J Am Acad Dermatol* 2008;58:719-37.
- Fitzpatrick RE, Goldman MP, Satur NM, Tope WD. Pulsed carbon dioxide laser resurfacing of photoaged facial skin. *Arch Dermatol* 1996;132:395-402.
- Nanni CA, Alster TS. Complications of carbon dioxide laser resurfacing. An evaluation of 500 patients. *Dermatol Surg* 1998;24:315-20.
- Glaich AS, Rahman Z, Goldberg LH, Friedman PM. Fractional resurfacing for the treatment of hypopigmented scars: A pilot study. *Dermatol Surg* 2007;33:289-94.
- Hasegawa T, Matsukura T, Mizuno Y, Suga Y, Ogawa H, Ikeda S, *et al.* Clinical trial of a laser device called fractional photothermolysis system for acne scars. *J Dermatol* 2006;33:623-7.
- Behroozan DS, Goldberg LH, Dai T, Geronemus RG, Friedman PM. Fractional photothermolysis for the treatment of surgical scars: A case report. *J Cosmet Laser Ther* 2006;8:35-8.
- Bhardwaj D, Khunger N. An assessment of the efficacy and safety of CROSS technique with 100% TCA in the management of ice pick acne scars. *J Cutan Aesthet Surg* 2010;3:93-6.
- Goodman GJ. Treating scars: Addressing surface, volume, and movement to expedite optimal results. Part 2: More-severe grades of scarring. *Dermatol Surg* 2012;38:1310-21.
- Fisher GH, Geronemus RG. Short-term side effects of fractional photothermolysis. *Dermatol Surg* 2005;31:1245-9.
- Wanner M, Tanzi EL, Alster TS. Fractional photothermolysis: Treatment of facial and nonfacial cutaneous photodamage with a 1,550-nm erbium-doped fiber laser. *Dermatol Surg* 2007;33:23-8.
- Graber EM, Tanzi EL, Alster TS. Side effects and complications of fractional laser photothermolysis: Experience with 961 treatments. *Dermatol Surg* 2008;34:301-5.
- Kono T, Chan HH, Groff WF, Manstein D, Sakurai H, Takeuchi M, *et al.* Prospective direct comparison study of fractional resurfacing using different fluences and densities for skin rejuvenation in Asians. *Lasers Surg Med* 2007;39:311-4.
- Chan HH, Manstein D, Yu CS, Shek S, Kono T, Wei WI, *et al.* The prevalence and risk factors of post-inflammatory hyperpigmentation after fractional resurfacing in Asians. *Lasers Surg Med* 2007;39:381-5.
- Cho SB, Lee SJ, Kang JM, Kim YK, Chung WS, Oh SH, *et al.* The efficacy and safety of 10,600-nm carbon dioxide fractional laser for acne scars in Asian patients. *Dermatol Surg* 2009;35:1955-61.
- Chapas AM, Brightman L, Sukal S, Hale E, Daniel D, Bernstein LJ, *et al.* Successful treatment of acneiform scarring with CO<sub>2</sub> ablative fractional resurfacing. *Lasers Surg Med* 2008;40:381-6.
- Hedelund L, Haak CS, Togsverd-Bo K, Bogh MK, Bjerring P, Haedersdal M, *et al.* Fractional CO<sub>2</sub> laser resurfacing for atrophic acne scars: A randomized controlled trial with blinded response evaluation. *Lasers Surg Med* 2012;44:447-52.
- Kang WH, Kim YJ, Pyo WS, Park SJ, Kim JH. Atrophic acne scar treatment using triple combination therapy: Dot

- peeling, subcision and fractional laser. *J Cosmet Laser Ther* 2009;11:212-5.
35. Weiss R, Weiss M, Beasley K. Long-term Experience with Fixed Array 1540 Fractional Erbium Laser for Acne Scars. Kissimmee, FL: Abstract presented at American Society for Laser Medicine and Surgery Conference; 2008.
36. Sardana K, Manjhi M, Garg VK, Sagar V. Which type of atrophic acne scar (ice-pick, boxcar or rolling) responds to nonablative fractional. *Dermatol Surg* 2014;40:288-300.
37. Lee HS, Lee JH, Ahn GY, Lee DH, Shin JW, Kim DH, *et al.* Fractional photothermolysis for the treatment of acne scars: A report of 27 Korean patients. *J Dermatolog Treat* 2008;19:45-9.
38. Hedelund L, Moreau KE, Beyer DM, Nymann P, Haedersdal M. Fractional nonablative 1,540-nm laser resurfacing of atrophic acne scars. A randomized controlled trial with blinded response evaluation. *Lasers Med Sci* 2010;25:749-54.
39. Mahmoud BH, Srivastava D, Janiga JJ, Yang JJ, Lim HW, Ozog DM, *et al.* Safety and efficacy of erbium-doped yttrium aluminum garnet fractionated laser for treatment of acne scars in type IV to VI skin. *Dermatol Surg* 2010;36:602-9.

**How to cite this article:** Saeed AHM, Alsaiani SA. The efficacy of fractional CO<sub>2</sub> laser resurfacing in the treatment of facial acne scars. *Int J Med Sci Public Health* 2018;7(8):630-637.

**Source of Support:** Nil, **Conflict of Interest:** None declared.